

From: Parrack DO, Jonathan E
To: RUGGIERO, DOMINIC
Date of Procedure: 08/15/2018

Dominic,

You had 3 small polyps, 2 in the ascending colon and one at the hepatic flexure. These were all removed in their entirety. You also had scant outpouchings of the colon called diverticulosis as well as internal hemorrhoids.

With best regards,
Jonathan E Parrack, D.O.

YRMC CareConnect

◀ General Message

From: Parrack DO, Jonathan E
To: Swanson, Nathaniel M; RUGGIERO, DOMINIC
Sent: 08/20/2018 14:06:58 MST
Subject: General Message

Dominic,

I wanted to let you know that one of the polyps removed from the ascending colon resulted as a tubular adenoma, a benign but precancerous polyp in the type that we follow every 5 years. I will place you on a five-year recall list for colonoscopy. If you have any questions or concerns, please don't hesitate to contact me. It has been a pleasure working with you.

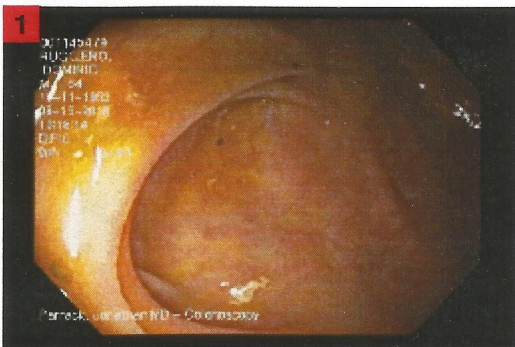
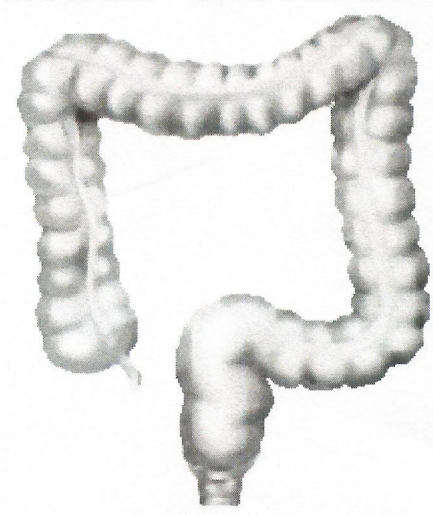
With best regards,

Jonathan E Parrack, D.O.

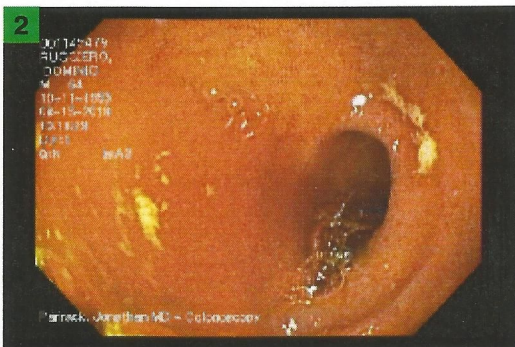Nathaniel -- five-year recall list for colonoscopy due to polyps, please copy his PCP

Yavapai Regional Medical Center

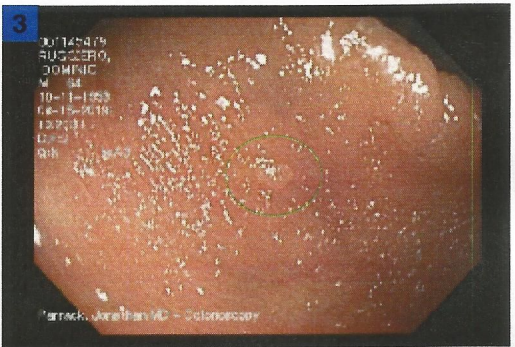Hospital ID: 001145479
PatientName: DOMINIC RUGGIERO
DOB: 10/11/1953
Procedure: Colonoscopy
Date: 08/15/2018 **Time:** 09:46:00 AM
Account #:
Endoscopist: Parrack, Jonathan MD



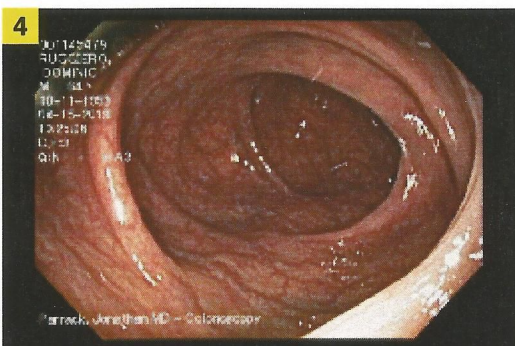
Appendiceal Orifice



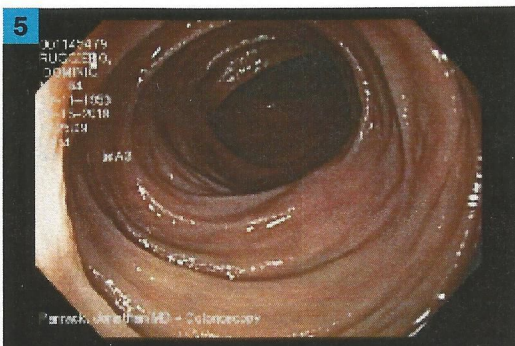
Terminal Ileum



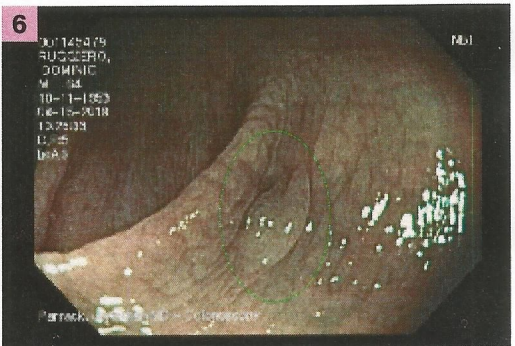
Ascending polyp



Normal Colon



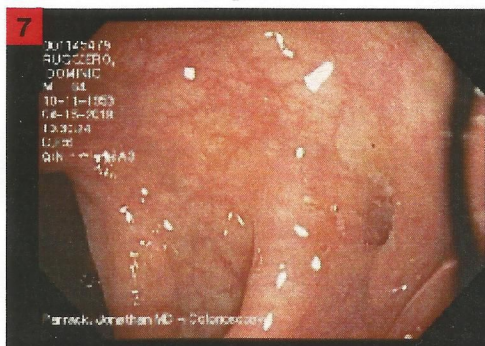
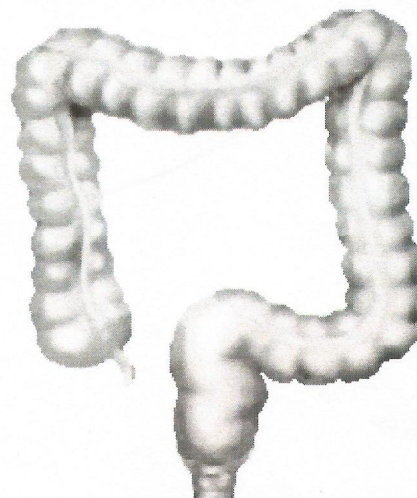
Normal Colon



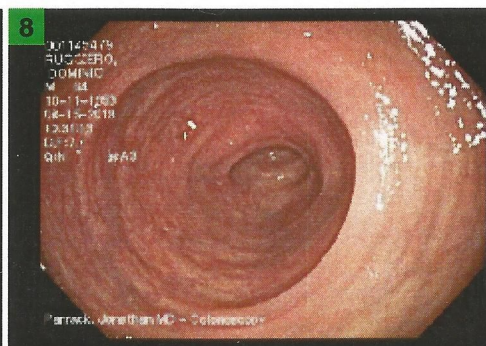
HF polyp

Yavapai Regional Medical Center

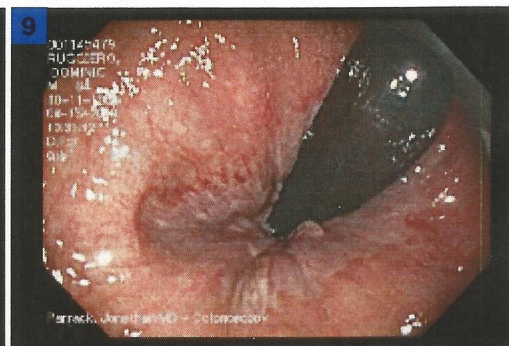
Hospital ID: 001145479
PatientName: DOMINIC RUGGIERO
DOB: 10/11/1953
Procedure: Colonoscopy
Date: 08/15/2018 **Time:** 09:46:00 AM
Account #:
Endoscopist: Parrack, Jonathan MD



Diverticulosis



Normal Colon



Internal Hemorrhoids